Could skin issues in people and pets be connected to Lewy body diseases? A focus on cherry (senile) angiomas

Jennifer Thornton, Independent Researcher and Author of "Mites, Microbes and Neurodegeneration: A unified environmental hypothesis for Parkinson's disease, Alzheimer's disease and Lewy body dementia" (Published in the Journal of Alzheimer's Disease 3/2026) and Published Book: *Saving My Family: The Rise of Parkinson's and Other Diseases*



INTRODUCTION

Cherry Angiomas Also Known As **Senile Hemangiomas**
Benign vascular skin lesions that often appear in clusters during episodes of **inflammation, immune activation, or cutaneous irritation.**
People and pets share the same living environments.
Exposure to similar microbes or mites (such as Cheyletiella or Demodex) may contribute to skin and systemic inflammation — potentially linking dermatologic conditions with neurological disease.

Key Study Finding-The Prevalence and Clinical Significance of Skin Manifestations in Parkinson's Disease Patients (Iyidal et al, 2024)
In a cross-sectional study of 215 Parkinson's disease (PD) patients:

- **45.1%** had cherry angiomas
- **79.3%** developed them before their PD diagnosis
- **This suggests cherry angiomas may act as visible early indicators of underlying disease processes.**

This Study explores cherry angiomas as potential non-motor or environmental markers associated with **Lewy Body Diseases (LBDs).**
Note: Multiple family members pictured here were also included in our article and my book (**available on Amazon for .99).**

Yellow Crust near Cherry (Senile) Angioma
Prior to his diagnosis of Lewy body dementia, the father developed new cherry angiomas, dry skin, seborrheic dermatitis, acute rosacea, and chronic unilateral ocular symptoms (diagnosed as mite infestation).

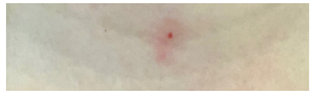

Teenager acquired Cherry Angioma
When the family dog had skin issues. Photograph obtained soon after the cherry angioma appeared.

METHODS & EVIDENCE

Photographic documentation and symptom logs were reviewed from a family reporting clusters of cherry angiomas, and sensations of biting after contact with household pets exhibiting dermatitis and seborrheic dermatitis. Observations were compared with published evidence describing skin manifestations in PD—particularly seborrheic dermatitis, dry skin, rosacea, and cherry angiomas (PMCID: PMC11620005).

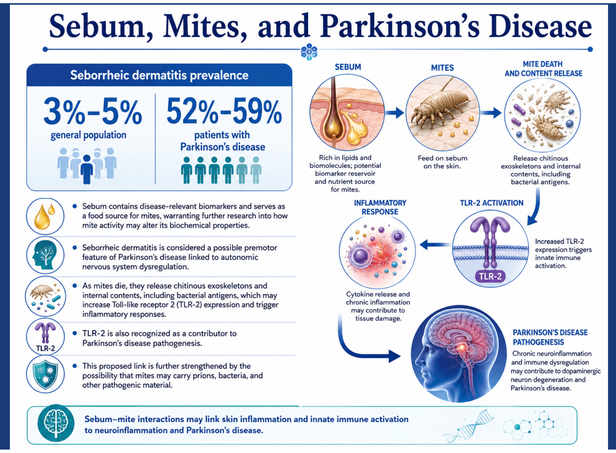

In patients with seborrheic dermatitis, researchers found four Malassezia species along with mites-primarily **Demodex brevis** at 65% and **Demodex follicolorum** at 26%-supporting a microbial/acarid component in seborrheic dermatitis.(Mokronosova, MA). **A Nationwide Study showed Scabies was associated with a 1.46 fold increased risk of Parkinson's Disease, while treatment with lindane (Pesticide) was linked to a significantly lower risk, suggesting a potential protective effect of lindane (PESTICIDE). (Tsai et al., 2024)**

RESULTS

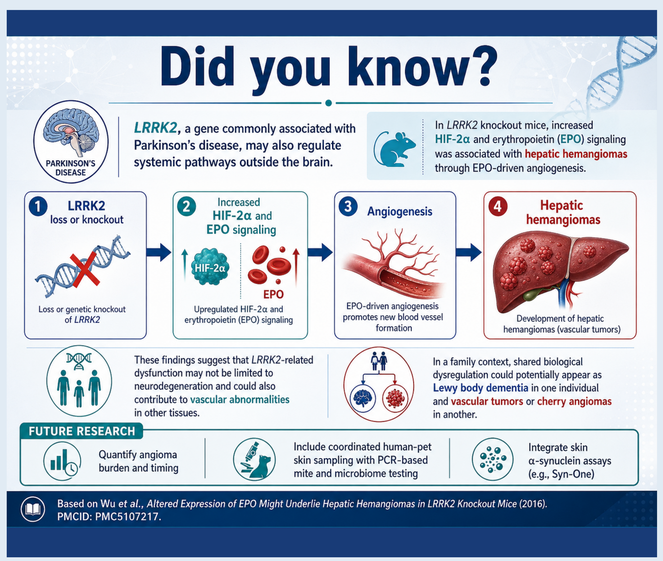

Clusters of new cherry angiomas appeared on multiple areas including the trunk, neck, scalp, and behind the ear regions after pet exposure. Some family members could feel mite bites while others were asymptomatic. One family member later developed Lewy body dementia, while another relative by marriage developed Parkinson's symptoms (tremors, obstructive sleep apnea, dystonia). Both individuals exhibited new-onset cherry angiomas and other cutaneous abnormalities preceding neurological decline. Two family members were diagnosed with internal hemangiomas. One in the neck area where bites occurred and the other in the liver (an area where she had pain when her sinuses drained, she believes the mites were in her eye and nasal passage/sinuses).

CONCLUSION

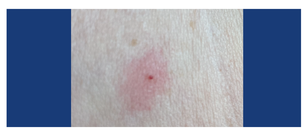

Cherry Angioma
Photograph obtained immediately after a middle-aged family member reported a biting sensation, showing a cherry angioma with surrounding erythema.

Cherry angiomas may represent an underrecognized, non-motor biomarker of Lewy body diseases. Given their frequency, visibility, and potential to precede motor onset, routine dermatologic screening could complement neurological assessment in PD and LBD. Cherry angiomas may represent an underrecognized, non-motor biomarker of Lewy body diseases. Given their frequency, visibility, and potential to precede motor onset, routine dermatologic screening could complement neurological assessment in PD and LBD. Future research should (i) quantify angioma burden and temporal onset, (ii) include coordinated human–pet skin sampling with PCR-based mite and microbiome testing, and (iii) integrate skin α-synuclein assays (e.g., Syn-One). Clarifying whether cherry angiomas act as markers—or mediators—of inflammatory and vascular dysregulation may uncover new avenues for early detection and disease-modifying intervention.

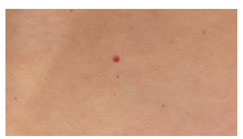

Cherry Angioma
Outbreak on middle-aged female prior to being diagnosed with multiple liver hemangiomas including one that was 10cm.

ACKNOWLEDGEMENTS

I wish to express my deepest gratitude to my beloved late father, whose documented disease journey continues to inspire this work; to the love of my life and my children, thank you for being pillars of support throughout this journey, to my mother, Linda Shy, for her extraordinary advocacy and unwavering support; Dr. Jenny Stevenson, Julie Whitten, Jane Scarborough, Dr. Bianca Kroettinger, Grace Galligher, Esq., Dr. Mary Newport, and Angela Bertke for their invaluable guidance and contributions over the years; and to my friends, family, and all who offered steadfast encouragement throughout this journey. To Dr. George Perry and the Journal of Alzheimer's Disease, thank you for your support and publishing our article.

SCAN ME

Created with BioRender Poster Builder